

Cornea Verticillata – a Rare Complication of Chloroquine Toxicity. Case Report

Emilia Babula¹, Natalia Winiarska¹, Katarzyna Samelska^{2,3}, Justyna Izdebska^{2,3}

¹ Student Scientific Society The Eye, Department of Ophthalmology, Medical University of Warsaw

² Department of Ophthalmology, Medical University of Warsaw

³ SPKSO Ophthalmic University Hospital in Warsaw

Abstract:

Introduction: Cornea verticillata is characterized by bilateral grayish or golden-brown linear opacities in a typical vortex shape, mainly in the lower segments of the corneal epithelium, without covering the corneal stroma. It is most often associated with taking amiodarone but can be induced by other medications. Chloroquine is commonly used in treatment and prevention of protozoal diseases. Additionally, it has applications in dermatology and rheumatology as an anti-inflammatory agent in collagenosis, rheumatoid arthritis or lupus erythematosus. Its ophthalmic side effects and their management are noteworthy and are briefly summarized in this paper.

Material and methods: We present a case of a 62-year-old female patient who was referred to the clinic for diagnosis of corneal lesions detected incidentally during a follow-up examination 6 months after starting treatment with chloroquine for rheumatoid arthritis.

Results: The patient was diagnosed with cornea verticillata and informed that it does not affect visual acuity and is not an indication for changes in therapy. Discontinuation of medication results in partial or, in some cases, complete resolution of changes.

Discussion: It is important to closely monitor patients taking drugs that are known to have ophthalmic side effects for the first time in new indications. We should consider eye side effects when treating systemic disease and recommend screening tests.

Conclusions: A baseline ophthalmic examination should be performed on all patients before initiating use of chloroquine. Moreover, chloroquine can lead to permanent loss of visual acuity contributing to bull's eye maculopathy, which is irreversible.

Key words:

cornea, corneal diseases, chloroquine, arthritis, rheumatoid, drug-related side effects and adverse reactions.

Introduction

Vortex keratopathy (cornea verticillata) is described as a bilateral whorl-shaped dystrophy of the cornea with a fine stippling of the Bowman's membrane epithelium. It is characterized by brownish to golden and greyish opacities arranged in curved lines, mainly in the lower segments of the corneal epithelium, without covering the corneal stroma [1]. Usually it is associated with the use of systemic drugs such as amiodaron and aminoquinolines (chloroquine, hydroxychloroquine, mepacrine), but it can be induced by chlorpromazine, tamoxifen, nonsteroidal anti-inflammatory drugs (NSAIDs), some antibiotics, kinase inhibitors, antibody-drug conjugates and gold [2]. It is generally asymptomatic, although some patients experience subjective symptoms such as a sensation of foggy. The visual acuity is intact, and the lesions tend to subside when the triggering substance is withdrawn [1, 2]. Chloroquine (CQ) was initially used as an antimalarial drug but found application in rheumatology, dermatology and oncology. Although cases of vortex keratopathy caused by CQ have been described [3], in ophthalmology it is mostly associated with irreversible retinopathy. Systemic side effects include lesions in the heart, nerves and kidneys, and most are reversible by stopping the treatment [4].

Material and methods

A 62-year-old woman was referred to our ophthalmology clinic for assessment of corneal changes detected in a regular eye examination. She reported no symptoms related to the lesions, with no visual complaints or significant ocular history. Otherwise, her drug history comprised chloroquine intake for the past 6 months due to rheumatoid arthritis.

On initial presentation, the uncorrected visual acuity was 5/5 in both the right eye (RE) and the left eye (LE). Short-distance visual acuity, with correction (+3.5 Dsph), was 0.5 in both eyes. Additionally, results from the Amsler test and intraocular pressure examination fell within the normal range.

In the slit-lamp examination, haze was limited to the corneal epithelium, extending across the entire corneal surface. No indications of conjunctival redness, blepharitis, peripheral corneal vascularization, or dry eye disease were observed (Fig. 1.). Anterior segment slit-lamp photography further revealed haze in the deep layers of the epithelium in both eyes. Additionally, bilateral fine brownish linear deposits were noted in the lower segments of the corneal epithelium, with no signs of stromal swelling or visible endothelial abnormalities (Fig. 2.).

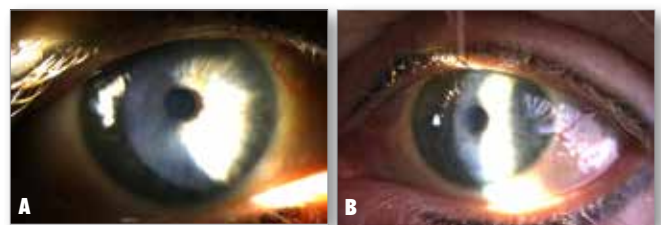


Fig. 1. Right eye (A) and left eye (B) seen in the slit-lamp examination.

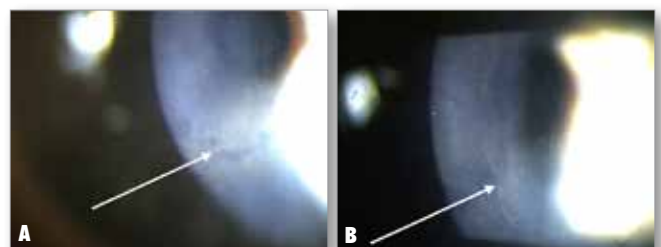


Fig. 2. After 6 months of chloroquine treatment, anterior segment slit-lamp photography of the right eye (C) and left eye (D) revealed a haze in the deep layers of the corneal epithelium. Bilateral observations included fine golden-brown linear deposits in the lower segments of the corneal epithelium (white arrows), with no signs of stromal swelling or visible endothelial dysfunction.

The fundus examination showed satisfactory results, with no apparent abnormalities in the macula. Vessels were assessed as adequate for the patient's age, and the retina was normal and adherent.

In addition, confocal microscopy (Confoscan) was conducted. It revealed bilaterally observed hyperreflective circular opacities in the deep layers of the corneal epithelium, with no anomalies detected in the stroma or endothelium (Fig. 3.).




Fig. 3. Confocal microscopy – Confoscan.

Results

Based on these signs, the patient was diagnosed with bilateral vortex keratopathy related to chloroquine use. As vortex keratopathy commonly manifests with whorl-like pattern deposits, the diagnosis was not evident, underscoring the necessity for a comprehensive differential evaluation.

Vortex keratopathy is not an absolute indication to discontinue the treatment. We recommended maintaining the current therapeutic regimen and a follow-up visit at 6 months. However, the patient's rheumatologist decided to discontinue chloroquine treatment due to other adverse effects, not related to the ophthalmic examination.

At the follow-up visit at 6 months after discontinuation of chloroquine, the examination revealed a marginal decrease in corneal lesions in both eyes. However, the patient's corneas still demonstrated fine pigmentary linear patterns and corneal haze consistent with the presentation of vortex keratopathy. Complete resolution of vortex keratopathy had not been achieved. Repeated confocal microscopy (Confoscan) demonstrated persistent isolated hyperreflective deposits (Fig. 4.). There was no change in visual acuity, which remained within normal limits for both distance and near vision.




Fig. 4. Confocal microscopy (Confoscan) after 6 months from discontinuation of chloroquine treatment.

Discussion

Cornea verticillata usually is a benign dystrophy that does not affect patients' vision and subsides after discontinuing the treat-

ment. Vortex keratopathy induced by amiodarone has been successfully cleared by topical use of heparin solution; however, the presented results came from a single patient's case and should be considered with caution [5]. It is also not known whether they can be translated to cases where the disease was caused by another drug. The question remains whether actions aimed at reducing it make sense from the clinical point of view. A much more important issue is the ophthalmic toxicity of drugs administered systemically, in this case chloroquine.

Various ophthalmic side effects for CQ have been described. The risk depends on the total duration of treatment, the prescribed dose and preexisting conditions such as maculopathy or diabetes-induced retinopathy. It is therefore crucial to rule out risk factors before starting the treatment, and an ophthalmologist's consultation is indicated. The changes can affect both the anterior part of the eye and the retina. While keratopathy rarely alters vision, difficulty with proper accommodation has been reported. Patients have also described photophobia and halos around light sources [3]. These changes resolve after withdrawing the medications, but it is also possible for them to disappear despite continuation of therapy. Retinopathy caused by CQ is usually defined as bull's eye change in the fundus, is irreversible and can progress even after the drugs are discontinued (Fig. 5.). There is no specific treatment for CQ-induced retinopathy; therefore prevention and early recognition are the key to maintaining patients' visual acuity. The aim is to minimize stress on the foveal region of the eye by avoiding direct sunlight or diabetes and hypertension control. Some authors recommend lutein (10–20 mg per day) and zeaxanthin supplementation (1–4 mg per day) [3]. When deciding to withdraw the drug, both the patient and attending doctor must consider the risk-to-benefit ratio. Threat to vision must be acknowledged when continuing the therapy for better control of the underlying disease.

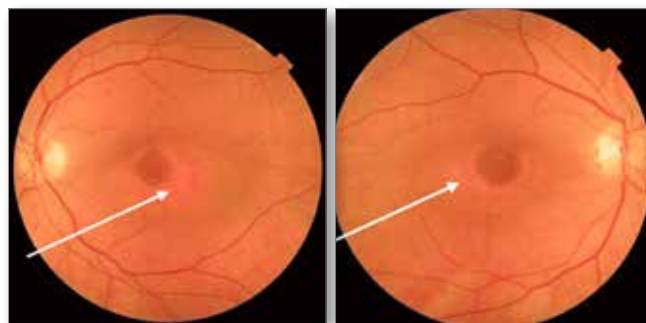


Fig. 5. Bull's eye maculopathy – irreversible depigmentation in the perifoveal area of the retina (white arrows).

Recommendations for screening patients who have taken CQ and hydroxychloroquine (HCQ) are regularly updated. The strongest evidence points to annual screening for patients in therapy with CQ for 1 year or longer. A good clinical practice would be performing examination every 6 months, including color fundus photography and spectral domain optical coherence tomography [6].

During the COVID-19 outbreak, CQ and HCQ were used for management of the infection, which provoked some safety concerns, especially considering the unusually large doses that were administered [7]. CQ and HCQ can also be used in the treatment of dry eye disease (ocular surface disease index lower for CQ/HCQ in comparison with the control group – $p < 0.0001$) [8]. It is important to closely monitor patients taking drugs that are known to have ophthalmic side effects for the first time in new indications. Clinical vigilance is advised as new reports of complications are emerging all the time and a seemingly benign clinical

presentation may cause an oversight of a serious conditions. A case of vortex keratopathy was reported to lead to intraocular lymphoma diagnosis [9]. Similarly, the occurrence of cornea verticillata can be an indicator of Fabry disease in patients with an uncertain diagnosis, but absence of keratopathy cannot exclude the disease [10]. Differential diagnosis for vortex keratopathy should also involve paraproteinemias such as multiple myeloma or Waldenström macroglobulinemia [2].

Conclusions

Cornea verticillata should not be associated only with amiodarone.

Baseline ophthalmic examination should be performed in all patients before initiating use of chloroquine.

Chloroquine can lead to permanent loss of visual acuity, contributing to bull's eye maculopathy, which is irreversible.

Ophthalmic side effects and appropriate screening for them should be considered when treating systemic diseases.

Disclosure

The authors declare no conflict of interest.

References:

1. François J: *Cornea verticillata*. Doc Ophthalmol. 1969. <https://doi.org/10.1007/bf00208693>
2. Raizman MB, Hamrah P, Holland EJ, Kim T, Mah FS, Rapuano CJ, et al.: *Drug-induced corneal epithelial changes*. Surv Ophthalmol. May-Jun 2017. <https://doi.org/10.1016/j.survophthal.2016.11.008>
3. Costedoat-Chalumeau N, Dunogué B, Leroux G, Morel N, Jallouli M, Le Guern V, et al.: *A Critical Review of the Effects of Hydroxychloroquine and Chloroquine on the Eye*. Clin Rev Allergy Immunol. Dec 2015. <https://doi.org/10.1007/s12016-015-8469-8>
4. Celotto S, Veronese N, Barbagallo M, Ometto F, Smith L, Pardhan S, et al.: *An umbrella review of systematic reviews with meta-analyses evaluating positive and negative outcomes of Hydroxychloroquine and chloroquine therapy*. Int J Infect Dis. Feb 2021. <https://doi.org/10.1016/j.ijid.2020.12.018>
5. Frings A, Schargus M: *Recovery From Amiodarone-Induced Cornea Verticillata by Application of Topical Heparin*. Cornea. Nov 2017. <https://doi.org/10.1097/ico.0000000000001306>
6. Yusuf IH, Foot B, Galloway J, Ardern-Jones MR, Watson SL, Yelf C, et al.: *The Royal College of Ophthalmologists recommendations on screening for hydroxychloroquine and chloroquine users in the United Kingdom: executive summary*. Eye (Lond). Jul 2018. <https://doi.org/10.1038/s41433-018-0136-x>
7. Nicolò M, Ferro Desideri L, Bassetti M, Traverso CE: *Hydroxychloroquine and chloroquine retinal safety concerns during COVID-19 outbreak*. Int Ophthalmol. Feb 2021. <https://doi.org/10.1007/s10792-020-01593-0>
8. Prinz J, Maffulli N, Fuest M, Walter P, Hildebrand F, Migliorini F: *Chloroquine and Hydroxychloroquine in the Treatment of Dry Eye Disease*. Diseases. Jun 12 2023. <https://doi.org/10.3390/diseases11020085>
9. Hasan N, Narde HK, Das AK, Chawla R: *Unusual presentation of cornea verticillata with intravitreal methotrexate in a case of primary intraocular lymphoma*. BMJ Case Rep. Jan 13 2022. <https://doi.org/10.1136/bcr-2021-246911>
10. van der Tol L, Sminia ML, Hollak CE, Biegstraaten M: *Cornea verticillata supports a diagnosis of Fabry disease in non-classical phenotypes: results from the Dutch cohort and a systematic review*. Br J Ophthalmol. Jan 2016. <https://doi.org/10.1136/bjophthalmol-2014-306433>

Reprint requests to:

Emilia Babula (e-mail: ebabula99@gmail.com)